

ANATOMICAL AND MORPHOLOGICAL STRUCTURE OF *PEGANUM HARMALA* OF ALMATY REGION AND ITS THERAPEUTIC PROPERTIES

SEILKHAN A.S.¹, KUDRINA N.O.^{2,3}, CHEREPKOVA N.V.^{2,3}, KULMANOV T.E.²,
KURMANBAYEVA M.S.³, INELOVA Z.A.^{3*} AND SHALGIMBAYEVA S.M.³

¹Kazakh National Agrarian University; Almaty, Kazakhstan

²Laboratory of Pharmacodynamics and Immunopharmacology RSE Central Laboratory for Biocontrol, Certification and Preclinical Testing; Almaty, Kazakhstan

³Al-Farabi Kazakh National University, Department of Biodiversity and Bioresources.

*Corresponding author's email: z.inelova2015@gmail.com

Abstract

Peganum harmala L. (harmal) is a perennial herbaceous, multistage plant, having an ancient history of use for disinfection purposes, and in modern medicine, the relevance to the widespread use of the multi-purpose therapeutic properties of this species has increased. Evaluation of raw material base of harmal will allow balanced use as a dye and alkaloid medicinal plant in certified medicine. *Peganum harmala* L. showed resistance to external influences, since the influence of various environmental factors on the soil cover of southeast Kazakhstan led to an increase in degraded areas, in which it was found abundant growth of this plant. The results of geobotanical studies carried out over the last 2015-2018 show that the raw material base of *Peganum harmala* L. causes wide application in medicine. In connection with the rich resource of *Peganum harmala* L., it shows interest of local and domestic consumers for the application of raw materials in the form of an extract. In laboratory conditions, to identify signs of resistance to various conditions, complex studies were conducted to the morphological and anatomical structure. Morphological characteristic and the anatomical structure of *Peganum harmala* L. were determined. Signs of stability are ring-shaped sclerenchyma in stems and roots, as well as the presence of a two-sided columnar mesophyll in leaves. To assess the therapeutic properties *Peganum harmala* L. experimental studies were conducted in the laboratory of pharmacodynamics and immunopharmacology and the influence of the water-alcohol extract of this plant on the metabolism of rats with alimentary obesity was investigated.

Key words: *Peganum harmala*, Anatomical structure, Water-alcohol extract, Alimentary obesity.

Introduction

Peganum harmala (harmal) of the family Peganaceae is a plant widespread in the territory of Kazakhstan, namely in the Ile in the southwestern part of the sand of Taukum in the Ile region of the Akshi village and further in the sands for 20-40 km. Also we surveyed a site from the village Kurti to the village Aydarly with coverage of the adjacent territory within a radius of 20-30 km on the territory of Zhambyl district of Almaty region. 76°23'16,056"E 44°40'16,52"N. A rich resource of plant *P. harmala*, allows to widely study it and apply it in the field of medicine (Adekenov *et al.*, 2010).

In-depth research the anatomical properties of the *Peganum harmala* L. have been studied. Assemblage of rootlets of the plants are woody, and the caulis grassy, leave amphistomatic (Koyuncu *et al.*, 2008).

In Algerian highlands were studied the anatomical characteristics and contents of common alkaloids of *Peganum harmala* (:Sassoui & Seridi, 2013). Flower development and vascular anatomy are investigated in *Peganum harmala*, emphasizing its unusual androecium with 15 stamens. Sepals arise consistently; petals appear simultaneously with five refractory stamens (Decraene *et al.*, 1996). On ultrastructural observations, the plastids of secretory cells in the early stages of development were rich in starch grains, but they disappeared as nectar developed (Abedini *et al.*, 2013).

Characteristics and chemical compound of *P. harmala* are studied all over the world, in the composition detected quinazoline, beta-carboline alkaloids-peganin (vasicine), desoxypeganin (desoxyvasicine), peganini glycoside (Herraiz *et al.*, 2017;). A total of 105 compounds were identified, the main components of which are oxygenated monoterpenes oxygenated sesquiterpenes, alkaloids of quinazoline have bronchodilatory and imperfectly formed

effect (Herraiz *et al.*, 2017; Ayoob *et al.*, 2017; Apostolico *et al.*, 2016). From seeds of *P. harmala* detached rare alkaloid-peganumaline and peganumaline F of alkaloid enantiomers with early unknown carbon skeleton, the isolates were tested for antiproliferative and antibacterial activity Wang *et al.*, 2018. From seeds of *P. harmala* seventeen quinazoline alkaloids and derivatives, containing new epimers were extracted (Li *et al.*, 2018). A wide range of effects of *P. harmala* is shown, including antibacterial, antifungal, antiviral, antioxidant, antidiabetic, antineoplastic, insecticidal, cytotoxic and hepatoprotective (Asgarpanah & Ramezanloo, 2012). *P. harmala* seed oil components are characterized - tocopherol and linoleic acid, *in vivo* shown anti-inflammatory, analgesic activity and antioxidant capacity, that the cream of *P. harmala* seed oil has anti-inflammatory activity and analgesic effect (Khadhr *et al.*, 2017). *Peganum harmala* seeds treated with microwaves, used to synthesize a new adsorbent (Agarwal *et al.*, 2017).

P. harmala seeds antiviral effect for hepatitis A and genital herpes has been proven (Moradi *et al.*, 2017; Benzekri *et al.*, 2018). Powder of *P. harmala* seed, coated with nanoparticles ZnO is used for absorption of Cr (VI) (Fazlzadeh *et al.*, 2017). In alternative medicine *P. harmala* used to treat memory disorders, it has a beneficial effect on learning processes in mice, plant is recommended as a valuable source for meds development in the treatment of memory disorders, Senile Dementia of the Alzheimer Type (Liu *et al.*, 2017). The cytotoxic effect of *P. harmala* against a variety of tested cancer cell lines is shown, including those resistant to chemotherapy (Ayoob *et al.*, 2017; Mashhadi *et al.*, 2017; Wang *et al.*, 2017; Bournine *et al.*, 2016; Wang *et al.*, 2016). Antibacterial activity against *Escherichia coli* and *Staphylococcus aureus* has shown moderate inhibitory effects demonstrating its antibacterial value against pathogenic diseases (Azizi *et al.*, 2017). Active compounds

of *P. harmala* have a pronounced acaricidal activity against *Psoroptes cuniculi* and can be widely used for the treatment of acariasis in animals (Shang *et al.*, 2016). Diuretic action of the *P. harmala* is shown, so the plant can be used as an effective diuretic (Al-Saikhan & Ansari, 2016). In intoxication CCl₄ the therapeutic effect of protein 132 KD, which educed from seeds of *P. harmala*, revealed that the isolated protein has a pronounced antioxidant activity (Soliman *et al.*, 2013). It has been experimentally confirmed that *P. harmala* affects the metabolism of rat lipids, the use of *P. harmala* reduces the level of total cholesterol and low-density cholesterol in the blood, increasing the effect of cholesterol excretion (Kalhor *et al.*, 2015). Many scientific papers have been devoted to the study of alimentary obesity with plant extracts (McManus *et al.*, 2015, Ierardi *et al.*, 2016) Mohammadi *et al.*, 2016; Quintieri *et al.*, 2016).

Drinking with added plant stanol esters effectively reduces the total serum cholesterol and LDL cholesterol in hypercholesterolemic patients after two weeks (Lestiani *et al.*, 2018). It is shown that the *P. harmala* seed extract is effective in the treatment of chronic ethanol intoxication. Combined introduction of *P. harmala* and ethanol inhibited lipid peroxidation and improved antioxidant activity, it is shown that treatment with *P. harmala* extract effectively protects hepatic function of rats with alcoholic intoxication and reduces the level of aminotransferase (Bourogaa *et al.*, 2016).

It is also shown that the methanol extract of *P. harmala* can be effectively used for broilers to optimize the profile of serum lipids, reduce the cost of feed and maximize gross income (Tanweer *et al.*, 2013. At present, the biochemical parameters of blood have been studied in an experiment on the model of diabetes mellitus with the use of *P. harmala* water extracts. It was shown that the ALT, LDL-C, TG and creatinine was restored to healthy control levels after 4 weeks of treatment with the extract, it was experimentally confirmed that the water-alcohol extract of *P. harmala* seeds has antidiabetic and lipid-lowering activity and can be useful in the treatment of diabetes (Gaballu *et al.*, 2015; Komeili *et al.*, 2016). *P. harmala* is recommended by many authors as a raw material for an effective natural preparation for preclinical and clinical studies (Niroumand *et al.*, 2015; Azizi *et al.*, 2017; Liu *et al.*, 2017).

In this study, we evaluated the effect of the water-alcohol extract of *P. harmala* on blood glucose, lipid profile, liver function, and protein metabolism in rats with alimentary obesity.

Materials and Methods

P. harmala was collected on the territories in the Kurti district of Almaty region. Initially, from the specimen of the herbarium, morphological characteristics of the species were detailed (Gemedzhieva *et al.*, 2016). The plant species was confirmed at the Department of Biodiversity and Bioresources of al-Farabi Kazakh National University. Anatomical structure of the parts of *P. harmala* was studied in accordance with the methods of Terletskaya *et al.*, (2017). For the anatomical study of the part of the plant, the root, stem and leaf of *P. harmala* fixed in a 70% solution of alcohol in the 1:1:1 ratios of water, glycerin. Anatomic sections with a thickness of 15 μm were obtained using a cryotome, the preparations

were encapsulated in glycerin, the micrographs were made on a microscope MC-300, Micros Austria.

For statistical analysis, sections were made from 15 plants. More than 200 sections were prepared.

Experimental studies were conducted in compliance with the ethical standards in the laboratory of pharmacodynamics and immunopharmacology of RSE Central Laboratory for Biocontrol, Certification and Preclinical Testing. For the study, white rats were selected at the age of 6 months. Rats weighing 200-250 g were kept in standard laboratory conditions at a temperature of 20±3 °C. All animals received a normal diet of vivarium and water in excess.

For the experiment, 40 male rats were used, the animals were divided into control and experimental groups. The model of alimentary obesity was formed by introducing into the diet of animals products containing high doses of cholesterol for 28 days (Apyatin *et al.*, 2016; Onopchenko *et al.*, 2014). All rats with a model of alimentary obesity were divided into 3 groups and received 50, 100 and 200 mg/kg of *P. harmala* extract daily for 28 days (Komeili *et al.*, 2016, Kalhor *et al.*, 2015).

Daily monitoring of the experimental animals was carried out, at the end of the experiment all the rats were blood sampled. *P. harmala* was collected in the Almaty region in 2015. The ground portion of the plant was dried, homogenized into a powder and placed in a dark glass container at a rate of 30 g with a 60% ethanol solution to obtain a 20% aqueous alcohol solution and left for 24 hours in a thermostat at 37°C. During the experiments, before oral supplementation, the extract was further dissolved in water, and the animals were forcibly fed. Both in the control and in the experimental group, rats received 50, 100 and 200 mg / kg of water-alcohol extract of *P. harmala* daily.

The analysis of the clinical chemistry of sera from experimental animals was carried out on an automatic biochemical analyzer BioChem FC-200 and semi-automatic biochemical analyzer LIHD116 Screen Master Touch with the use of commercial reagents BioSystems S.A.

The statistical processing of the results was carried out using of V. Lakin programs (link if available) and Student's t-test.

Results

Anatomical features. For anatomical studies, samples were taken from the root, stem and leaves of plants.

Root: The thickness of the root is 3481, 99±12,15μm. Due to the fact that the plant is considered perennial covering cloth is periderm. Periderma covers a very large area, the thickness of which is 232,55±0,55μm, periderma perform the functions of endurance and resistance of plants against external influences. The thickness of the cortex 549,16±1,19 μm, consists of sclerenchyma cells and parenchyma. In the central cylinder, we can distinguish phloem formed by 2-3-layer cells, and a layer of cambium between phloem and xylem, and the main central part completely embraces the xylem. Diameter of the central cylinder - 2700±5,78 μm. In the central cylinder, we can distinguish phloem formed by 2-3-layer cells, and a layer of cambium between phloem and xylem, and the main central part completely embraces the xylem (Fig. 1, Table 1).

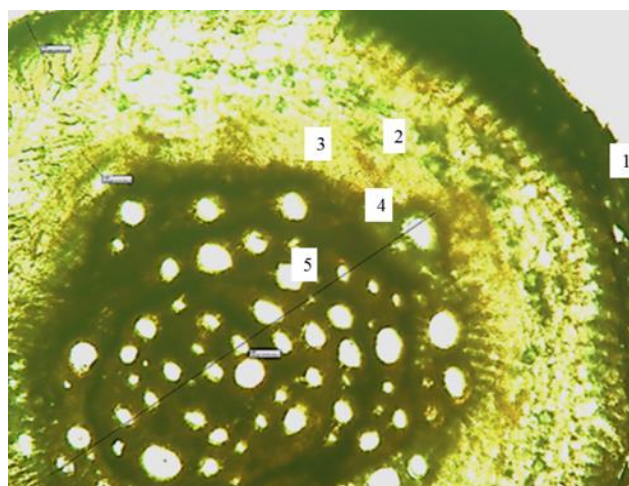


Fig. 1. Transverse section of root *P.harmala*: enlarge.100. 1- periderma; 2- cortex; 3- phloem;4- cambium,5-xylem

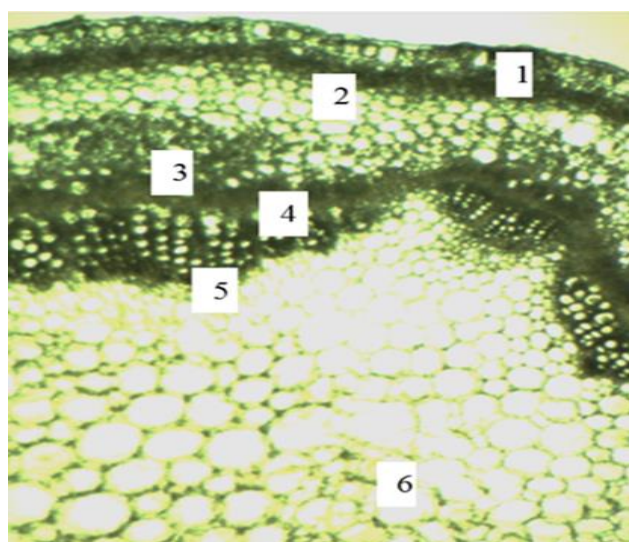


Fig. 2. Transverse structure of the stem *P.harmala*:enlarged. 100. 1- epidermis; 2-ring sclerenchyma; 3-phloem; 4-cambium; 5-xylem; 6-parenchyma of the core.

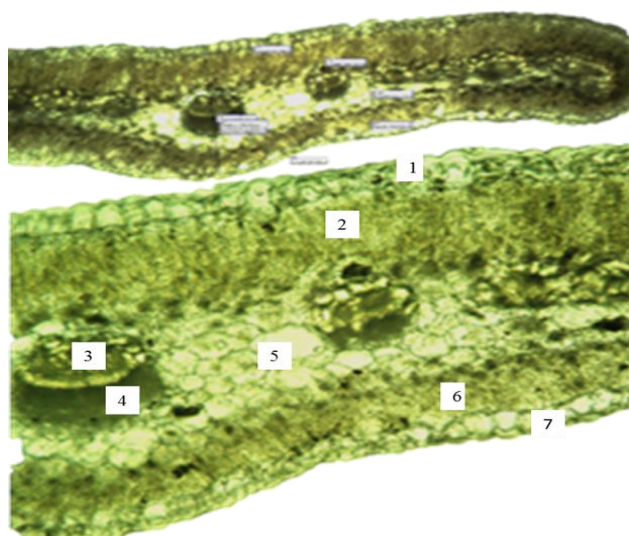


Fig. 3. Transverse leaf structure *P.harmala*: enlarged 100. 1- upper epidermis; 2-columned mesophyll; 3-xylem; 4-xylem; 5- spongy mesophyll; columnar mesophyll; 7-lower epidermis

The thickness of the root is $3481,99 \pm 12,15 \mu\text{m}$. In the anatomical structures of the *P. harmala* root, the root is covered with the secondary covering tissue by periderm. The periderma occupies a small area and its thickness is $232.55 \pm 0.55 \mu\text{m}$. A significant part of the cortex is covered by an annular sclerenchyma, and this ring of sclerenchyma performs the functions of endurance and resistance of the plant against external influences. The thickness of the *P. harmala* bark is $549.16 \pm 1.19 \mu\text{m}$, which consists of sclerenchyma cells and parenchyma. In the central cylinder, one can distinguish phloem formed by 2-3-layer cells and a layer of cambium between phloem and xylem, and the main central part completely embraces the xylem. The diameter of the central cylinder is $2700 \pm 5.78 \mu\text{m}$. The xylem vessel has a double wall. On the outer side of the xylem there is an even thinner cell wall, consisting of a small inner dense wall and large parenchymatous cells (Fig. 1, Table 1).

A feature of the anatomical structure of the root is that the cortex consists of a thick layer of annular sclerenchyma, and the vessel of xylem has a double shell, the revealed anatomical signs give the root an essential strength.

Stem: In the transverse section, the stem consists of the epidermis, the cortex and the central vascular cylinder. The cells of the epidermis are strongly cutinized. Under the cells of the epidermis, a small part of the cortex is made up of parenchymal cells. In the cortex, after the layer of parenchymatous cells, an annular sclerenchyma is located. Under the ring of sclerenchyma, the parenchymal cells of the cortex come from 5-6 layers. The thickness of the primary cortex is $568.00 \pm 2.45 \mu\text{m}$. The thickness of the central cylinder is $2616.01 \pm 4.78 \mu\text{m}$. The phloem is well developed in the central cylinder and there is a clear separation of phloem from xylem with a continuous thick cambium layer. An identical ratio of phloem to xylem was observed by alternating continuous beams. The core of the stem was completely filled with parenchymatous cells of various sizes (Fig. 2, Table 1).

On the transverse section of the stem, the presence of an annular sclerenchyma was determined, which in turn shows signs of adaptation to an external factor.

Leaf: In the anatomical structures of the leaf, it was observed that the outer walls of the epidermal cells are highly cutinized as from the upper and so on the lower side. The thickness of the transverse section of the leaf was $2424.12 \pm 14.43 \mu\text{m}$. In the transverse section of the leaf, the outer side of the upper epidermis had a thick cuticle. The epidermal cells had different sizes. The thickness of the upper epidermis was $168.76 \pm 0.9 \mu\text{m}$, and the lower epidermis was 144.22 ± 0.7 . The peculiarity of *P. harmala* is that the leaf structure has a double columnar mesophyll. In this case, its thickness was $408.08 \pm 2.4 \mu\text{m}$ under the upper epidermis and under the lower epidermis $296.43 \pm 1.3 \mu\text{m}$, the thickness of the spongy mesophyll is $1032.77 \pm 4.7 \mu\text{m}$. The columnar mesophyll under the upper epidermis is most developed in comparison with the mesophyll which borders on the lower epidermis. The vascular bundles of the *P. harmala* leaf consist of xylem and phloem, beneath the phloem

there is a sclerenchyma. Conductive beams are in the spongy mesophyll which consist of chlorenchyma cells. The vascular bundles of the *P. harmala* leaf consist of xylem and phloem, beneath the phloem the sclerenchyma was located, the bundles were surrounded by chlorenchyma. The central vein is located on the central beam (Fig. 3, Table 1).

A feature on anatomical structure of leaf of the medicinal plant *P. harmala* is that the epidermis is strongly cutinized, the characteristic is characteristic of xerophytes, and columnar mesophylls are also found on both sides, which cause resistance to various external influences of the environment.

Animal study: In order to determine the therapeutic properties of *P. harmala*, a water-alcohol extract was obtained, which was used to detect the effect on the metabolism in alimentary obesity in rats.

According to our data, shown in Table 1, in the group of obesity rats there was a statistically significant increase in the level of GGT and ALT level in comparison with the

intact group ($p < 0,05$). In terms of total, direct bilirubin, AST and AP, no significant changes were observed.

According to the results of Table 1, in the control group of animals taking *P. harmala* extract 100 and 200 mg/kg, a statistically significant increase in the level of alanine aminotransferase ($p < 0,05$). Analysis of the results of the GGT level showed a statistically significant increase in the level of GGT in rats with a model of alimentary obesity and against the background of *P. harmala* extract ($p < 0,05$).

Based on the results of Table 2, the high cholesterol diet led to a statistically significant ($p \leq 0.5$) increase in the level of Triglycerides, Cholesterol, total, dLDL-Cholesterol in rats ($p < 0,05$) compared to the intact group.

Daily enteral administration of the *P. harmala* extract resulted in a statistically significant decrease in the level of Triglycerides, Cholesterol, total, dLDL-Cholesterol ($p < 0,05$) in experimental animals.

Along with this, with alimentary obesity in rats, there was a statistically significant decrease in the albumin level, Creatinin and Glucose ($p < 0,05$) (Table 3).

Table 1. Morphometric data of the anatomical structure of the *P. harmala*.

Root			
Root thickness, μm	Periderm, μm	Cortex, μm	Diameter of the central cylinder, μm
3481,99 \pm 12,15	232,55 \pm 0,55	549,16 \pm 1,19	2700 \pm 5,78
Stem			
Epidermis, μm	Primary cortex, μm	Ploema, μm	Xylem, μm
107,33 \pm 1,34	368,19 \pm 2, 32	296,17 \pm 0,23	336,10 \pm 1,64
Leaf			
Leaf thickness, μm	Upper epidermis, μm	Lower epidermis, μm	Center beam area, m^2
2424,12 \pm 14,43	168,76 \pm 0,9	144,22 \pm 0,7	125663,70

Table 2. Liver function indices for control and treatment in rats.

The group is alive / marker	Bilirubin total	Bilirubin direct	Bilirubin in Dir	GGT	ALT	AST	Alkaline phosphatase
Intact	13,4 \pm 2,06	3,32 \pm 0,64	10,08 \pm 1,96	20,96 \pm 2,11	2,36 \pm 0,16	1,04 \pm 0,22	1,74 \pm 0,48
Control 50mg/kg ext	15,28 \pm 1,95	4,00 \pm 0,81	11,28 \pm 1,36	23,8 \pm 5,91	3,02 \pm 0,88	1,56 \pm 0,45	1,74 \pm 0,48
Control 100mg/kg ext	14,1 \pm 3,10	4,88 \pm 1,16	9,22 \pm 3,03	26,0 \pm 7,24	4,92 \pm 0,23*	2,16 \pm 0,50	2,02 \pm 0,66
Control 200mg/kg ext	15,28 \pm 1,63	4,16 \pm 0,50	11,12 \pm 1,13	24,8 \pm 4,71	3,62 \pm 0,54*	2,04 \pm 0,12	2,14 \pm 0,16
Obecity	15,64 \pm 1,99	4,42 \pm 0,80	11,22 \pm 1,78	32,8 \pm 2,48*	3,07 \pm 0,20*	1,64 \pm 0,40	2,42 \pm 0,30
Obecity 50mg/kg ext	15,16 \pm 2,63	4,52 \pm 0,79	10,64 \pm 1,85	31,00 \pm 2,19**	3,02 \pm 0,22	1,58 \pm 0,26	2,18 \pm 0,17
Obecity 100mg/kg ext	15,28 \pm 1,63	4,16 \pm 0,50	11,12 \pm 1,13	33,6 \pm 1,50**	3,14 \pm 0,44	1,52 \pm 0,20	2,99 \pm 0,51
Obecity 200mg/kg ext	15,36 \pm 2,32	4,42 \pm 0,80	10,94 \pm 1,62	33,80 \pm 3,12**	3,20 \pm 0,41	1,70 \pm 0,18	2,54 \pm 1,26

*Statistically significant ($p \leq 0.5$)

Table 3. Lipid metabolism for control and treatments in rats.

Group of animals / marker	Triglycerides	Cholesterol, total	dHDL-Cholesterol	dLDL-Cholesterol
Intact	0,74 \pm 0,02	2,68 \pm 0,31	1,02 \pm 0,15	1,24 \pm 0,10
Control 50mg/kg ext	0,78 \pm 0,09	2,58 \pm 0,20	0,86 \pm 0,15	1,60 \pm 0,03
Control 100mg/kg ext	0,66 \pm 0,08	2,52 \pm 0,1	1,10 \pm 0,15	1,42 \pm 0,29
Control 200mg/kg ext	0,64 \pm 0,05	2,14 \pm 0,16	0,86 \pm 0,16	1,28 \pm 0,13
Obecity	0,98 \pm 0,07*	4,55 \pm 0,09*	1,20 \pm 0,06	2,64 \pm 0,10*
Obecity 50mg/kg ext	0,86 \pm 0,08	3,72 \pm 0,20**	1,28 \pm 0,12	2,44 \pm 0,21
Obecity 100mg/kg ext	0,82 \pm 0,04	3,20 \pm 0,21**	1,24 \pm 0,10	1,96 \pm 0,14**
Obecity 200mg/kg ext	0,78 \pm 0,07**	3,28 \pm 0,44**	1,22 \pm 0,17	1,86 \pm 0,09**

*Statistically significant

Table 4. Protein metabolism and glucose of control and treated rats.

Group of animals /marker	Protein, total	Albumin	BUN urea nitrogen	Uric acid	Creatinin	Glucose
Intact	66,58±2,09	26,60±1,02	12,70±0,89	404,20±29,48	88,80±3,97	6,04±0,16
Control 50mg/kg ext	66,00±3,16	27,20±1,60	14,00±2,35	382,20±22,65	99,20±3,49	6,28±0,61
Control 100mg/kg ext	63,74±2,99	23,60±1,85	13,28±1,08	362,40±35,52	93,20±7,93	6,06±0,74
Control 200mg/kg ext	66,14±2,51	27,60±1,02	13,18±1,23	370,20±20,90	101,00±3,35	6,26±0,22
Obecity	68,44±2,91	30,60±1,36*	14,02±1,72	382,20±22,65	107,20±3,25*	7,53±0,20*
Obecity 50mg/kg ext	67,62±3,46	28,20±1,33	13,04±0,80	386,60±27,24	103,60±3,44	7,44±0,46
Obecity 100mg/kg ext	66,00±1,79	29,60±1,02	14,8±20,4	395,20±30,43	106,40±8,14	6,96±0,08**
Obecity 200mg/kg ext	64,40±2,42	29,60±1,02	13,40±1,50	400,60±32,18	106,00±3,79	6,70±0,22**

*Statistically significant (p<0-0.5)

In addition, the data showed that alimentary obesity causes a significant increase in glucose, triglycerides, total cholesterol, and LDL-c (p<0,05). The intake of the water-alcohol extract of *P. harmala* statistically significantly reduces the glucose (p<0,05).

Discussion

This study was conducted to determine the effect of the introduction of the water-alcohol extract. We believe that important studies discovered in the study of the anatomy and morphology of *P. harmala* will lead to a better understanding of the species and will contribute to any future research (Koyuncu *et al.*, 2008, Niroumand *et al.*, 2015, Abedini *et al.*, 2013, Ronse Decraene *et al.*, 1996). This study was conducted to determine the effect of the introduction of the water-alcohol extract of *P. harmala* on the biochemical parameters of carbohydrate, lipid and protein metabolism and liver function of healthy rats, and also with induced alimentary obesity for 28 days (Table 4). In our study, alimentary obesity in rats was accompanied by an increase in the level of glucose, total cholesterol and low-density lipoprotein cholesterol, triglycerides, i.e. changes in the lipid profile, increased activity of the enzyme gamma glutamyltranspeptidase.

When the *P. harmala* extract was taken within 28 days, the parameters began to return to physiological. According to Komeili *et al.*, (2016) the introduction of an extract to diabetic rats resulted in a significant decrease in glucose, lipid, MDA, ALT, AST, GGT, bilirubin and HbA (1C) levels and an increase in TAC compared with the untreated diabetic group is consistent with our results. Most likely, the factor involved in reducing blood glucose is the presence of flavonoids, which have antihypercholesterolemic and antidiabetic properties (Komeili *et al.*, 2016, Kalhor *et al.*, 2015). It is also impossible to exclude the hypoglycemic effect of quinazoline, beta-carbolines of alkaloids (Herraiz *et al.*, 2017). Since only 105 compounds have been identified from *P. harmala*, the main components of which are oxygenated monoterpenes and sesquiterpenes, rare alkaloids-peganumaline and peganumaline F alkaloid enantiomers, seventeen quinazoline alkaloids and derivatives containing new epimers, it is impossible to exclude the complex effect of *P. harmala* components on the level of glucose in the blood and lipids (Herraiz *et al.*, 2017; Ayoob *et al.*, 2017; Apostolico *et al.*, 2016; Wang *et al.*, 2018; Li, *et al.*, 2018). Also, we confirmed the data of Kalhor *et al.*, 2015, about the effect of *P. harmala* on the metabolism of lipids in rats, including the reduction of total cholesterol and low density

cholesterol in the blood. According to Gaballu *et al.*, 2015, ALT, LDL-C, TG and creatinine were restored to healthy control levels after 4 weeks of treatment with the extract in the treatment of induced diabetes. It is known that hyperlipidemia is one of the characteristic symptoms of obesity and, in the absence of adequate therapy, leads to metabolic disorders, diabetes mellitus, impaired liver function (Obrosova *et al.*, 2017). The hypolipidemic effect of *P. harmala* may have an indirect effect on the modification of hepatic enzymes. Our data showed that functional liver tests, such as ALT, AST and bilirubin against a background of alimentary obesity, that *P. harmala* extracts possess hepatoprotective properties. We confirmed experimentally that the water-alcohol extract of *P. harmala* can be useful in the treatment of alimentary obesity, metabolic syndrome and as a consequence, pre-diabetes.

Based on the foregoing, we can recommend *P. harmala* as a raw material for a natural pharmaceutical or biologically active additive for combating obesity, metabolic disorders and pre-diabetes with preclinical and clinical studies.

Conclusion

As a result of analysis of the anatomical structures of *P. harmala* Almaty region a peculiar structure was observed, which implies that the columnar mesophyll in the leaves are found on both sides. In the structure of the stem, an annular sclerenchyma was seen between the parenchyma layers, as well as the same ratio of phloem to xylem.

The results of our study demonstrate that the water-alcohol extract of *P. harmala* Almaty region lowers the level of glucose in alimentary obesity and has a hypolipidemic effect. We consider it necessary to carry out further research to obtain purified extracts and to take full advantage of all the known therapeutic properties of *P. harmala* extracts.

References

- Abedini, M., A. Movafeghi, M. Aliasgharpour and M.R. Dadpour. 2013. Anatomy and ultrastructure of the floral nectary in *Peganum harmala* L. *Plant Species Biol.*, 528(3): 185-192.
- Adekenov, S.M., I.O. Baitulin, R.A. Egeubaeva and N.A. Saparbayeva. 2010. The current state of natural thickets of normal common in southern Kazakhstan. *Biol. & Med. Series*, 5: 55-61.

- Agarwal, S., V.K. Gupta, M. Ghasemi and J.A. Azimi. 2017. *Peganum harmala* L. seeds adsorbent for the rapid removal of noxious brilliant green dyes from aqueous phase *J. Mol. Liquids*, 231: 296-305.
- Al-Saikhan, F.I. and M.N. Ansari. 2016. Evaluation of the diuretic and urinary electrolyte effects of methanolic extract of *P. harmala* L. in Wistar albino rats. *Saudi J. Biol. Sci.*, 23(6): 749-753.
- Apostolico, I., L. Aliberti, L. Caputo, F. Fratianni, F. Nazzaro, L.F. Souza and M. Khadhr. 2016. Chemical composition, antibacterial and phytotoxic activities of *Peganum harmala* seed essential oils from five different localities in Northern Africa. *Molecules*. 21(9).pii: E1235. doi: 10.3390/molecules 21091235.
- Apryatin, S.A., K.V. Mzhelskaya, N.V. Trusov, A.S. Balakina, S.N. Kulakova, S.K. Soto, M.A. Makarenko, N.A. Riger and V.A. Tutelyan. 2016. Comparative characteristics of in vivo models of hyperlipidemia in Wistar rats and C57Bl/6 mice. *Vopr Pitan.*, 85(6): 14-23.
- Asgarpanah, J. and F. Ramezanloo. 2012. Chemistry, pharmacology and medicinal properties of *Peganum harmala* L. *Afr. J. Pharm. & Pharmacol.*, 6: 1573-1580.
- Ayoob, I., Y.M. Hazari, S.H. Lone, Shakeel-U-Rehman, M.A. Khuroo, K.M. Fazili and K.A. Bhat, 2017. Phytochemical and cytotoxic evaluation of *Peganum Harmala*: Structure activity relationship studies of Harmine. *Chem. Select.*, 2: 2965-2968.
- Azizi, M., S. Sedaghat, K. Tahvildari, P. Derakhshi and A. Ghaemi. 2017. Synthesis of silver nanoparticles using *Peganum harmala* extract as a green route. *Green Chem. Lett. & Rev.*, 10: 420-427.
- Benzekri, R., L. Bouzlama, A. Papetti, M. Hammami, A. Smaoui and F. Limam. 2018. Anti HSV-2 activity of *Peganum harmala* (L.) and isolation of the active compound. *Microbial. Pathogen*, 114: 291-298.
- Bournine, L., S. Bensalem, S. Fatmi, F. Bedjou, V. Mathieu, M. Iguer-Ouada, R. Kiss and P. Duez. 2016. Evaluation of the cytotoxic and cytostatic activities of alkaloid extracts from different parts of *Peganum harmala* L. (Zygophyllaceae). *Europ. J. Integ. Med.*, 9: 91-96.
- Bourogaa, E., R.M. Jarraya, M. Damak and A. Elfeki. 2015. Hepatoprotective activity of *Peganum harmala* against ethanol-induced liver damages in rats. *Arch. Physiol. & Biochem.*, 121(2): 62-67.
- Decraene, L.P.R., J. DeLaet and E.F. Smets. 1996. Morphological studies in Zygophyllaceae .2. The floral development and vascular anatomy of *Peganum harmala*. *Amer. J. Bot.*, 83(2): 201-215.
- Fazlzadeh, M., R. Khosravi and A. Zarei. 2017. Green synthesis of zinc oxide nanoparticles using *Peganum harmala* seed extract, and loaded on *Peganum harmala* seed powdered activated carbon as new adsorbent for removal of Cr(VI) from aqueous solution. *Ecol. Engin.*, 103: 180-190.
- Gaballu, F.A., Y.A. Gaballu, O.M. Khyavy, A. Mardomi, K. Ghahremanzadeh, B. Shokouhi and H. Mamandy. 2015. Effects of a triplex mixture of *Peganum harmala*, *Rhus coriaria*, and *Urtica dioica* aqueous extracts on metabolic and histological parameters in diabetic rats. *Pharm. Biol.*, 53(8): 1104-1109.
- Gemedzhieva, N.G., K.L. Musaev, Z.H. Karzhaubekova, M.S. Ramazanova and R.B. Arysbaeva. 2016. The resources of normal in the valley of the river Ile (South Pribalkhash) //Preservation of plant diversity in botanical gardens: traditions, modernity, prospects: materials of the Intern. conf., dedicated. The 70th anniversary of the Central Siberian Botanical Garden (Novosibirsk, August 1- 8, 2016). - Novosibirsk: CSBMS of the SB RAS, pp.76-78.
- Herraiz, T., H. Guillen, V.J. Aran and A. Salgado. 2017. Identification, occurrence and activity of quinazoline alkaloids in *Peganum harmala*. *Food & Chem. Toxicol.*, 103: 261-269.
- Ierardi, E., G. Losurdo, C. Sorrentino, F. Giorgio, G. Rossi, A. Marinaro, K.R. Romagno, A. Di Leo and M. Principi. 2016. Macronutrient intakes in obese subjects with or without small intestinal bacterial overgrowth: an alimentary survey. *Scand. J. Gastroenterol.*, 51(3): 277-280.
- Kalhor, N., A.M. Eini, Y. Sharifi, H. Fazaely and M.A. Far. 2015. Effect of *Peganum harmala* L. on lipid metabolism and changes HMGCoA reductase in Hypercholesterolemia-induced male wistar rat. International Conference on Health and Health Psychology (ICH & HPSY). 5: 3-11.
- Khadhr, M.; D. Bousta, E. Hanane, L. El Mansouri, S. Boukhira, M. Lachkar, B. Jamoussi and S. Boukhchina. 2017. HPLC and GC-MS Analysis of Tunisian *Peganum harmala* seeds oil and evaluation of some biological activities. *Amer. J. Therapeutics*, 24(6): 706-712.
- Komeili, G., M. Hashemi and M.B. Niafar. 2016. Evaluation of antidiabetic and antihyperlipidemic effects of *Peganum harmala* seeds in diabetic rats. *Cholesterol*, doi: 10.1155/2016/7389864. Epub 2016 Apr 14.
- Koyuncu, O., D. Öztürk, E.D. Potoğlu and A. Kaplan. 2008. Anatomical and palynological studies on economically important *Peganum harmala* L. (Zygophyllaceae). *Biyolojik Çeşitlilik ve Koruma* (1): 109-1.
- Lestiani, L., D.N. Chandra, K. Laitinen, F.D. Ambarwati, P. Kuusisto and W. Lukito. 2018. Double blind randomized placebo controlled trial demonstrating serum cholesterol lowering efficacy of a smoothie drink with added plant stanol esters in an Indonesian population. *Cholesterol*, DOI: 10.1155/2018/4857473
- Li, S.G., K.B. Wang, C. Gong, Y. Bao, N.B. Qin, D.H. Li, Z.L. Li, J. Bai and H.M. Hua. 2018. Cytotoxic quinazoline alkaloids from the seeds of *Peganum harmala* *Bioorganic & Med. Chem. Lett.*, 28(2): 103-106.
- Liu, W., Y.D. Zhu, Y.L. Wang, S.L. Qi, Y.W. Wang, C. Ma, S.P. Li, B. Jiang, X.M. Cheng and Z.T. Wang. 2017. Anti-amnesic effect of extract and alkaloid fraction from aerial parts of *Peganum harmala* on scopolamine-induced memory deficits in mice. *J. Ethnopharm.*, 204: 95-106.
- Mashhadi, F.F., S. Salimi, F. Forouzandeh and N. Naghsh. 2017. Comparison of anticancer activity of hydroalcoholic extracts of *Curcuma longa* L., *Peganum harmala* L. and *Boswellia serrata* on HeLa cells. *Jundishapur J. Nat. Pharm. Prod.*, 12: e37336.
- McManus, B.L., R. Korpela, J.R. Speakman, J.F. Cryan, P.D. Cotter and K.N. Nilaweera. 2015. Bovine serum albumin as the dominant form of dietary protein reduces subcutaneous fat mass, plasma leptin and plasma corticosterone in high fat-fed C57/BL6J mice. *J. Nutr.*, 114(4): 654-662.
- Mohammadi, R.S., R. Bidaki, F. Mirdrikvand, S.N.M. Yazdi and P.Y. Anari. 2016. *Peganum Harmala* (Aspand) Intoxication; a Case Report. *Emergency*, 4(2): 106-107.
- Moradi, M.T., A. Karimi, F. Fotouhi, S. Kheiri and A. Torabi. 2017. In vitro and in vivo effects of *Peganum harmala* L. seeds extract against influenza A virus. *Avicenna J. Phytomed.*, 7(6): 519-530.
- Niroumand, M.C., M.H. Farzaei and G. Amin. 2015. Medicinal properties of *Peganum harmala* L. in traditional Iranian medicine and modern phytotherapy: a review. *J. Trad. Chinese Med.*, 35(1):104-109.
- Obrosova, I.G., O. Ilnytska, V.V. Lyzogubov, I.A. Pavlov, N. Mashtalir, J.L. Nadler and V.R. Drel. 2007. High-fat diet induced neuropathy of pre-diabetes and obesity: effects of "healthy" diet and aldose reductase inhibition. *Diabetes*, 56(10): 598-608.

- Onopchenko, O.V., G.V. Kosiakova, E.F. Meged, V.M. Klimashevsky and N.M. Hula. 2014. The effect of N-stearoylethanolamine on cholesterol content, fatty acid composition and protein carbonylation level in rats with alimentary obesity-induced insulin resistance. *Biochem. J.*, 86(6): 119-228.
- Quintieri, A.M., E. Filice, D. Amelio, T. Pasqua, F.R. Lupi, F. Scavello, P. Cantafio, C. Rocca, A. Lauria, C. Penna, B. De Cindio, M.C. Cerra and T. Angelone. 2016. The innovative "Bio-Oil Spread" prevents etabolic disorders and mediates preconditioning-like cardioprotection in rats. *Nutr. Metab. Cardiovasc. Dis.*, 26(7): 603-613.
- Ronse Decraene, L.P., J De Laet and E.F. Smets. 1996. Morphological studies in Zygophyllaceae. The floral development and vascular anatomy of *Peganum harmala*. *Amer. J. Bot.*, 83(2): 201-215.
- Sassoui, D. and R. Seridi. 2013. Anatomical characteristic and comparison enter the contents total alkaloids of *Peganum harmala* (Zygophyllaceae) the high plateaus of the area of Djelfa Algeria. *Planta Medica* (79): 1270-1271.
- Shang, X.F., X. Guo, B. Li, H. Pan, J.Y. Zhang, Y. Zhang and X.L. Miao. 2016. Microwave-assisted of three bioactive alkaloids from *Peganum harmala* L. and their acaricidal activity against *Psoroptes cuniculi* in vitro. *J. Ethnopharm.*, 192: 350-361.
- Soliman, A.M., H.S. Abu-El-Zahab and G.A. Alswiai. 2013. Efficacy evaluation of the protein isolated from *Peganum harmala* seeds as an antioxidant in liver of rats. *Asian Pacific J. Trop. Med.*, 6(4): 285-295.
- Tanweer, A.J., N. Chand, S. Khan, A. Sultan, M.S. Qureshi; A. Akhtar, M. Inam and Rafiullah. 2013. Association of *Peganum harmala* L. Supplementation with lipid profile and its economic benefit in broiler production *Pak. Veter. J.*, 33: 313-316.
- Terletskaya and M. Kurmanbayeva. 2017. Change in leaf anatomical parameters of seedlings of different wheat species under conditions of drought and salt stress. *Pak J. Bot.*, 49(3): 857-865
- Wang, C.H., Z.X. Zhang, Y.H. Wang and X.J. He. 2016. Cytotoxic constituents and mechanism from *Peganum harmala*. *Chem. & Biodiv.*, 13(7): 961-968.
- Wang, K.B., D.H. Li, Y. Bao, F. Cao, W.J. Wang, C. Lin, W. Bin, J Bai, Y.H. Pei, Y.K. Jing, D.Z. Yang, Z.L. Li and H.M. Hue. 2017. Structurally diverse alkaloids from the seeds of *Peganum harmala*. *J. Nat. Prod.*, 80(2): 551-559.
- Wang, K.B., X. Hu, S.G. Li, X.Y. Li, D.H. Li, J. Bai, Y.H. Pei, Z.L. Li and H.M. Hua. 2018. Racemic indole alkaloids from the seeds of *Peganum harmala*. *Fitoterapia*, 125: 155-160.

(Received for publication 5 March 2018)